

# Improvement of skin barrier by a cream containing an ethanol extract of Maitake mushroom on normal and xerosis skin

Mie Nagao<sup>1</sup>, Takashi Sato<sup>2</sup>, Akira Ito<sup>2</sup>, Shigeru Matsuzaki<sup>3</sup>, and Masao Takahashi<sup>1,4</sup>

<sup>1</sup>Heimat Co., Ltd., Chuo-ku, Tokyo 103-0027, <sup>2</sup>Department of Biochemistry and Molecular Biology, Tokyo University of Pharmacy and Life Sciences, Hachioji, Tokyo 192-0392, and <sup>3</sup>Yoshii Central Clinic, Tano-gun, Gunma 370-2132, Japan, and <sup>4</sup>Immuno Research Ltd., Auckland, New Zealand

## Introduction

Xerosis (dry skin) is defined as dehydration of stratum corneum and characterized by scales, fissures, erosion, and calluses on the skin, which thereby impairs the skin barrier function. In addition, most xerosis patients exhibit uncomfortable itching feelings or pain. Thus, structural and functional improvement of the impaired skin barrier may facilitate a treatment for xerosis and improve the quality of life of patients. On the other hand, sebum secreted from sebaceous glands plays an important role for maintaining physiological functions by forming a biological barrier on the skin. Since we found novel evidence that an ethanol extract of *Grifola frondosa* (Maitake mushroom) fruiting body, which is termed Gripin<sup>®</sup>, augments the sebum production in hamster sebocytes *in vivo* and *in vitro*, the Maitake extract might be an effective means of treating xerosis. In the present study, we performed a clinical trial investigation using a cream containing 0.2% Maitake ethanol extract (Maitake cream) (舞潤<sup>®</sup>, MaiJun) (Fig. 1) on the posterior antebrachial and crural skin of 60 patients with moderate to severe xerosis, and on the posterior antebrachial skin of healthy volunteers.

## Patients and Methods

Sixty xerosis patients (25 males and 35 females, 75-97 years old) and fifteen healthy volunteers (6 males and 9 females, 23-63 years old) were initially enrolled in the trial. Twelve and thirty-five patients completed the entire 1- and 5-week treatment (once a day) with 0.2% Maitake cream, respectively. All healthy volunteers completed the 4-week (28 days) treatment (three times a day) with 0.2% Maitake cream. Evaluation of treatment benefit was based on measurement of skin desquamation for the patients, and that of skin surface sebum and water content of stratum corneum using Corneometer CM825PC.



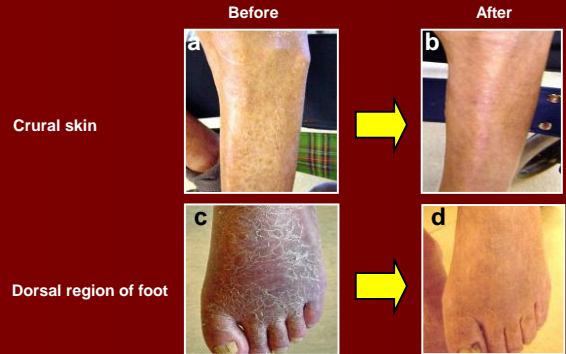**Fig. 1 Maitake cream**  
舞潤<sup>®</sup> (MaiJun) is a cream containing 0.2% Maitake ethanol extract (Gripin<sup>®</sup>).

## Results

- After 1-week of treatment with 0.2% Maitake cream, scales and fissures in the antebrachial and crural regions of patients were in remission (Fig. 2). In addition, clinical improvement was observed in most patients (Table 1).
- The 5-weeks treatment with 0.2% Maitake cream was found to decrease the grade from severe to moderate and mild by evaluation of the skin conditions in antebrachial [A] (36 regions in 18 patients,  $p < 0.01$ ) and crural regions [B] (34 regions in 17 patients,  $p < 0.05$ ) (Fig. 3).
- Topical application of 0.2% Maitake cream to posterior antebrachial skin of 15 healthy volunteers (three times a day for 28 days) showed the augmentation of water content of stratum corneum (<80%) (Table 2) and sebum levels on the skin (data not shown).
- The augmented effect of 0.2% Maitake cream on sebum and water content in the skin was detected after 1 day treatment, and sustained during our 4-week trial (Fig. 4).

## Conclusion

**These results suggest that the Maitake cream is useful for not only remission and/or cure of xerosis but also enhancement of moisturization in healthy skin by the mechanism whereby the Maitake extract augments sebum production to restore the cutaneous barrier function.**



**Fig. 2 Maitake cream is responsible for the cure of xerosis**  
Data show a male patient (77 years old) with moderate xerosis (panels a and c, Before). When the crural region and dorsal region of the feet of the patient were treated once a day with Maitake cream for 1 week, the skin condition was improved (panels b and d).

**Table 1 Improvement of the skin condition in posterior antebrachial and crural regions of patients with xerosis**

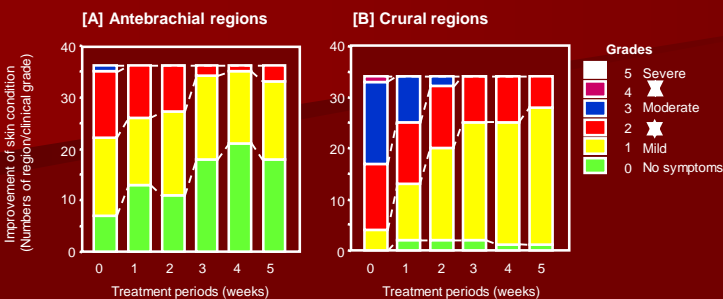
	Posterior antebrachial regions		Crural regions	
	Right	Left	Right	Left
Number of patients	9	11	12	12
Number of improved patients	7	10	12	10
Improvement rate (%)	77.8	90.9	100.0	83.3

When posterior antebrachial and crural regions of patients with xerosis were treated once a day for 1 week with 0.2% Maitake cream, the improvement of skin condition was evaluated by measurement of skin desquamation.

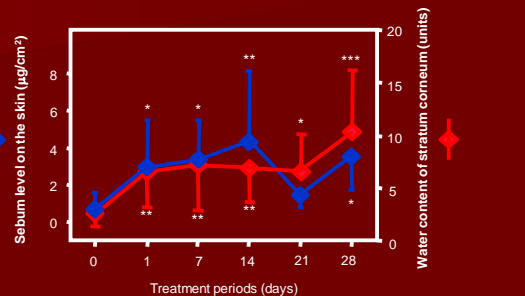
**Table 2 Augmentation of water content of stratum corneum by Maitake cream in healthy volunteers**

Treatments (days)	1	3	7	10	14	21	28
Numbers of volunteers	15	14	15	13	15	15	15
Numbers of improved volunteers	10	12	9	10	10	8	7
Improvement rate (%)	66.7	85.7	60.0	76.9	66.7	53.3	46.7

When 0.2% Maitake cream and vehicle cream were topically treated three times a day for 28 days on posterior antebrachial regions of fifteen healthy volunteers (23-63 years old), water content of stratum corneum was measured using Corneometer CM825PC.



**Fig. 3 Long-term treatment of Maitake cream improves skin condition in patients with xerosis**  
Statistical analysis was performed using Friedman test.



**Fig. 4 Augmentation of water content of stratum corneum and sebum on the skin in Maitake cream-treated healthy volunteers**

Data are shown as mean  $\pm$  SD of water content of stratum corneum (red diamonds) and sebum on the skin (blue diamonds) in both positively augmented healthy volunteers who were treated with 0.2% Maitake cream for 28 days. Statistical analysis was performed using ANOVA and Fisher test. \*, \*\*, and \*\*\*, significantly different from untreated volunteers (0 day) ( $p < 0.05$ , 0.01, and 0.001, respectively).